

Transluminal Stent-assisted Angioplasty of the Intracranial Vertebrobasilar System for Medically Refractory, Posterior Circulation Ischemia: Early Results

Elad I. Levy, M.D., Michael B. Horowitz, M.D.,
Christopher J. Koebbe, M.D.,
Charles C. Jungreis, M.D., G. Lee Pride, M.D.,
Kim Dutton, C.C.R.N., Philip D. Purdy, M.D.

Departments of Neurological Surgery (EIL, MBH, CJK, CCJ) and Radiology (MBH, CCJ), University of Pittsburgh Medical Center, Pittsburgh, Pennsylvania, and Departments of Neurosurgery (PDP) and Radiology (GLP, KD, PDP), University of Texas Southwestern Medical Center at Dallas, Dallas, Texas

OBJECTIVE: Symptomatic vertebrobasilar artery stenosis portends a poor prognosis, even with medical therapy. Surgical intervention is associated with considerable morbidity, and percutaneous angioplasty alone has demonstrated mixed results, with significant complications. Recent advances in stent technology have allowed for a novel treatment of symptomatic, medically refractory, vertebrobasilar artery stenosis. We report on a series of patients with medically refractory, posterior circulation stenosis who were treated with transluminal angioplasty and stenting at two medical centers in the United States.

METHODS: A retrospective analysis of data for 11 consecutive patients with symptomatic, medically refractory, intracranial, vertebral or basilar artery stenosis was performed. All patients were treated with percutaneous transluminal angioplasty and stenting. Short-term clinical and angiographic follow-up data were obtained.

RESULTS: Among 11 patients who were treated with stent-assisted angioplasty of the basilar or vertebral arteries, there were three periprocedural deaths and one delayed death after a pontine stroke. Other complications included a second pontine infarction, with subsequent residual diplopia. The remaining seven patients (64%) experienced symptom resolution and have resumed their preprocedural activities of daily living. Angiographic follow-up examinations demonstrated good patency of the stented lesions for five of seven survivors (71%); one patient exhibited minimal intrastent intimal hyperplasia, and another patient developed new stenosis proximal to the stent and also developed an aneurysm within the stented portion of the basilar artery. The last patient exhibited 40% narrowing of the treated portion of the vessel lumen.

CONCLUSION: Recent advances in stent technology allow negotiation of the proximal posterior circulation vasculature. Although the treatment of vertebrobasilar artery stenosis with angioplasty and stenting is promising, long-term angiographic and clinical follow-up monitoring of a larger patient population is needed. (*Neurosurgery* 48:1215–1223, 2001)

Key words: Angioplasty, Endovascular therapy, Stents

Symptomatic, medically refractory, basilar or vertebral artery stenosis portends a poor prognosis, with 5 to 11% of patients experiencing irreversible neurological deterioration or death (10.7/100 patient-yr) (2, 9, 15, 27, 31). With associated thrombosis or occlusion of the vertebrobasilar system, mortality rates are as high as 80 to 100% (15). Although surgical bypasses have been attempted, they are technically demanding and fraught with complications. Combined mortality and mor-

bidity rates of 34% are reported in some series (2, 9, 27). An alternative to surgical bypass is percutaneous transluminal angioplasty (PTA) (1, 8, 10, 14, 20). This treatment modality has demonstrated mixed results, with complications that include intraplaque dissection, embolic events, spasm, and restenosis in 20 to 30% of treated patients (7, 8, 12, 23).

The use of stent-assisted angioplasty in the coronary circulation improves outcomes and long-term patency, with a 93%

procedure success rate and a 2.1% incidence of restenosis requiring subsequent revascularization during a 3-year follow-up period (13). The rate of abrupt closure after coronary angioplasty alone can be as high as 28% in the presence of thrombus (3). With the developments of more compact and flexible stents (18), there exists the potential to negotiate the proximal vessels of the posterior circulation and deploy stents with the hope of hindering restenosis, treating dissections, and reducing the incidence of vessel recoil (16). Despite the potential benefits of stent-assisted angioplasty, the procedure is not risk-free (12, 16). We review the clinical and radiographic outcomes for 11 patients with symptomatic, medically intractable, posterior circulation ischemia treated with stent-assisted angioplasty of either the basilar or intracranial vertebral artery.

PATIENTS AND METHODS

Eleven patients with symptomatic, medically refractory, posterior circulation ischemia attributable to stenotic intracranial vertebral or basilar arteries were treated with stent-assisted angioplasty at the University of Pittsburgh Medical Center or the University of Texas Southwestern Medical Center at Dallas between February 1999 and January 2000. Three previously reported cases are included in this longer-term analysis (10). Medical records were reviewed for clinical outcomes, and angiography was completed during the last follow-up examination.

Table 1 presents the clinical characteristics for individual patients. The series consisted of 11 men, with a mean age of 63 years (range, 43–77 yr). All patients experienced failure of anticoagulation and/or antiplatelet therapy.

All patients presented with vertebrobasilar transient ischemic attacks or fixed deficits that failed to respond to heparin, warfarin, and antiplatelet medications. Symptoms included, but were not limited to, ataxia, facial droop, headaches, diplopia, incoordination, dysmetria, sensorimotor dysfunction, and depressed mental status. Two patients had experienced previous posterior circulation infarctions, and one patient had isolated syncope (Table 1). The locations and morphological features of the treated stenoses are presented in Table 2.

Procedure

Patients were administered general endotracheal anesthesia by the neuroanesthesia team. Administration of aspirin, clopidogrel, and heparin was not discontinued before the procedure. After placement of standard monitoring lines and femoral artery access sheaths, a bolus dose of 0.25 mg/kg abciximab (ReoPro; Eli Lilly and Co., Indianapolis, IN), a human platelet glycoprotein IIb/IIIa receptor inhibitor, was administered, followed by continuous infusion of 10 µg/min for 12 hours. The use of abciximab in the periprocedural period was previously well described by Horowitz et al. (10).

The activated clotting time was maintained between 200 and 250 seconds throughout the procedure. After diagnostic angiography to determine posterior circulation anatomic features and collateral circulation, a guide catheter was advanced into the appropriate vertebral artery and road-map images

TABLE 1. Patient Demographic Characteristics^a

Patient No.	Age (yr)/Sex	Comorbidities	Symptoms
1	62/M	HTN, CAD, MI, tobacco	VB TIA, hemiparesis
2	66/M	CAD, MI, DM, hyperlipidemia	VB TIA, thalamic stroke, BA thrombosis at admission
3	61/M	HTN, CAD, PVD, tobacco	VB TIA
4	65/M	HTN, CAD, AAA, tobacco	VB TIA, visual decline
5	77/M	HTN	Syncope
6	43/M	Tobacco	VB TIA, BA thrombosis at admission
7	56/M	HTN, PVD, hyperlipidemia	VB TIA
8	65/M	Tobacco	VB TIA
9	68/M	HTN, PVD	2 strokes, vertigo
10	65/M	HTN, PVD	VB TIA
11	64/M	HTN, PVD, CAD, COPD, hyperlipidemia, reflux	VB TIA

^a AAA, abdominal aortic aneurysm; CAD, coronary artery disease; COPD, chronic obstructive pulmonary disease; HTN, hypertension; PVD, peripheral vascular disease; VB, vertebrobasilar; TIA, transient ischemic attack; MI, myocardial infarction; DM, diabetes mellitus; BA, basilar artery.

were obtained. A 0.018-inch microcatheter was then advanced coaxially over a 0.016-inch wire into the distal vertebral or basilar artery, depending on the area necessitating treatment. A 0.014-inch, 300-cm, coronary exchange wire was then advanced through the catheter, and the microcatheter was removed. Pentothal burst suppression was provided by the neuroanesthesiologist in some cases, because of anticipated occlusion of the basilar artery during passage of the stent across the lesion. A preloaded coronary stent (Table 2) was then advanced over an exchange wire and positioned across the stenosis. We used stents from three manufacturers (Arterial Vascular Engineering-Medtronic, Santa Rosa, CA; Advanced Cardiovascular Systems, Santa Clara, CA; and NIR Medinol, Jerusalem, Israel). Occasionally, the stenosis was first predilated with a smaller coronary balloon, typically using a LeVeen inflator with inflation to 6 atmospheres for 5 seconds, to facilitate placement of the stent across the lesion (Ranger percutaneous transluminal coronary angioplasty; SCIMED, Maple Grove, MN). The stent was subsequently

TABLE 2. Lesion Location, Stent Size, and Complications^a

Patient No.	Lesion Location	Mori Classification	Stent Type and Size (mm)	Complication
1	Proximal BA	A	NIR 4 × 9	VA rupture
2	Distal BA stenosis, thrombosis at admission	C	ACS 3 × 13	Pontine stroke
3	Mid-BA stenosis	A	AVE 3 × 8	None
4	Mid-BA stenosis	A	NIR 3 × 9	None
5	Mid-BA stenosis	B	AVE 3 × 8	None
6	Proximal BA, thrombosed at admission	A	ACS 3 × 8	None
7	Mid-BA stenosis	A	AVE 4 × 12	None
8	Mid-BA stenosis	B	AVE 2.5 × 12	Brain death
9	Distal right VA stenosis (left VA occlusion)	A	AVE 3.5 × 18	None
10	Distal left VA stenosis (right VA occlusion)	A	AVE 3 × 12	None
11	Distal right VA stenosis (left VA occlusion)	C	AVE 2.5 × 12	VA rupture, death

^a BA, basilar artery; VA, vertebral artery; ACS, Advanced Cardiovascular Systems; AVE, Arterial Vascular Engineering-Medtronic; NIR, NIR Medinol.

deployed. After angiographic confirmation of improved luminal diameter, the balloon and guidewire were withdrawn. Computed tomographic scans were routinely obtained after the procedure, to rule out hemorrhage.

Postprocedure management

Heparin treatment was discontinued but not reversed. Abciximab administration was continued for the remainder of the 12-hour infusion period. Antiplatelet medication was administered as before the procedure. Coumadin treatment was

discontinued. The arterial sheath was removed the next day if no further angiography was planned. Patients were discharged receiving daily doses of 325 mg of aspirin and 75 mg of clopidogrel bisulfate (Plavix; Bristol-Myers Squibb, New York, NY). The latter treatment was discontinued after 30 days.

RESULTS

Patient outcomes, complications, and radiographic follow-up results are presented in *Table 3*. The mean clinical

TABLE 3. Clinical and Radiographic Outcomes^a

Patient No.	Clinical Outcome (Modified Rankin Scale Scores, Preoperative/Postoperative) ^b	Angiographic Follow-up Results	Follow-up Period (mo)
1	5/6	NA	<1
2	4/6	NA	3
3	1/0	Good patency	8
4	3/0	Minimal intimal hyperplasia	4
5	1/0	Good patency	6
6	1/0	40% narrowing, intimal hyperplasia	5
7	1/1	Good patency	5
8	1/6	NA	<1
9	2/0	Good patency	5
10	1/0	Good patency	3
11	1/6	NA	<1

^a NA, not available.

^b Modified Rankin Scale: 0, no symptoms; 1, minor symptoms; 2, minor handicap; 3, moderate handicap; 4, moderately severe handicap; 5, severe handicap; 6, death.

follow-up period was 4 months. Seven of 11 patients (64%) are no longer experiencing recurrent symptoms while receiving antiplatelet medication. All seven are home and have resumed activities of daily living at the same or better levels, compared with levels before their procedures (Fig. 1).

Two patients with long stenotic segments experienced rupture of the vertebral or basilar artery, which resulted in death (Fig. 2). Another patient developed a left pontine stroke after treatment of his basilar artery stenosis and died 3 months later in a nursing facility. One other patient, who exhibited severe mid-basilar artery stenosis (>5 mm in length) and underwent a seemingly uncomplicated procedure, experienced brain death after angioplasty-assisted stenting of the lesion (Table 3).

The mean angiographic follow-up period was 4 months (range, 3 d to 12 mo). Angiographic follow-up evaluations demonstrated good patency of the stented lesion for five of seven survivors (71%). One patient exhibited minimal intimal

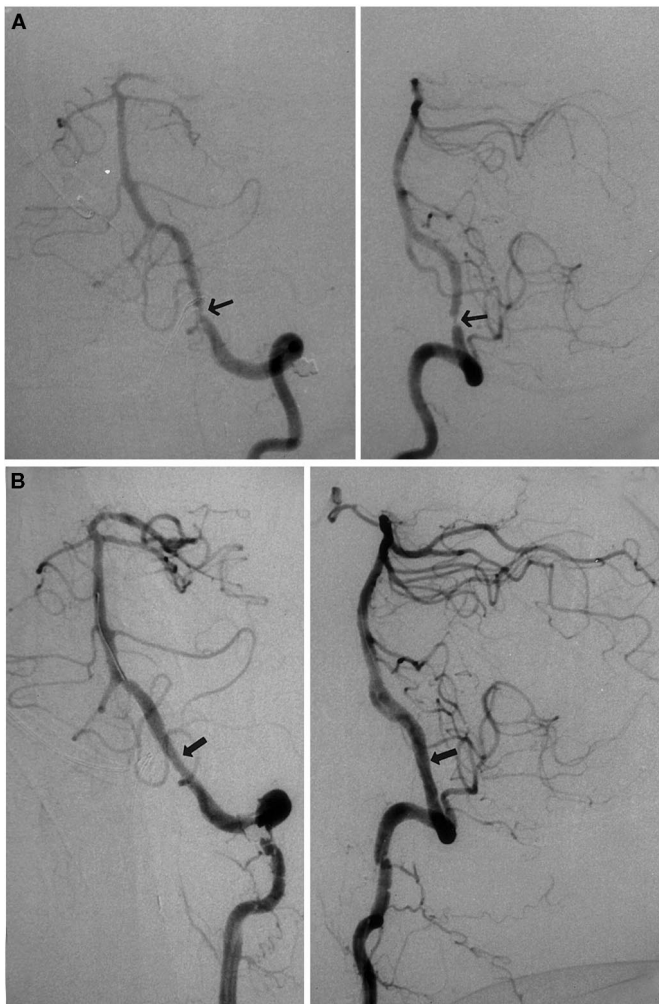


FIGURE 1. Patient 10. *A*, anteroposterior (*left*) and lateral (*right*) angiograms, demonstrating left vertebral artery stenosis (*arrows*). *B*, anteroposterior (*left*) and lateral (*right*) angiograms, showing the treated vessel after angioplasty and stenting (*arrows*).

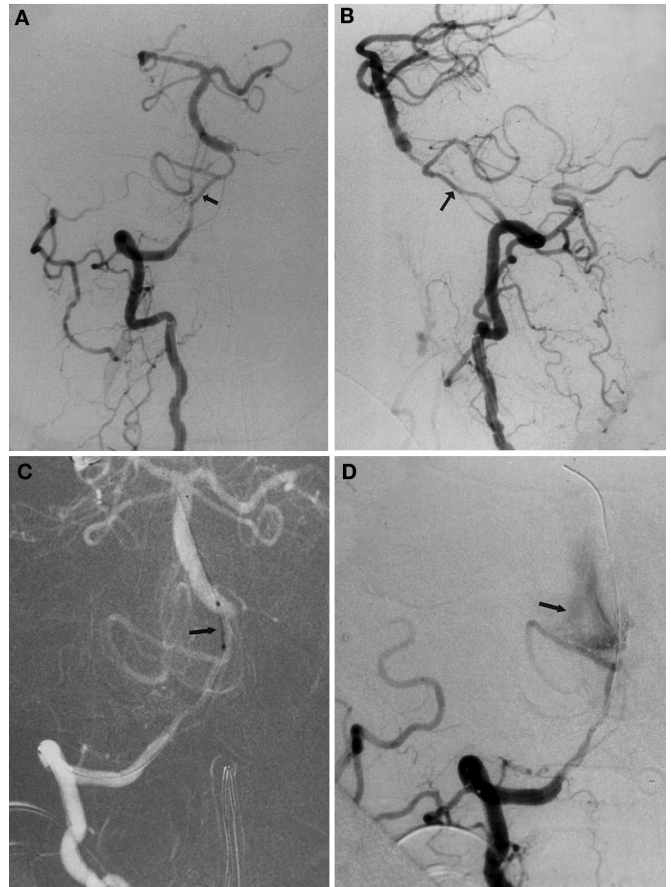


FIGURE 2. Patient 11. *A*, anteroposterior angiogram, showing long right vertebral artery stenosis (*arrow*). *B*, lateral angiogram, showing long right vertebral artery stenosis (*arrow*). *C*, anteroposterior angiogram showing the stent positioned at the vertebrobasilar junction before deployment (*arrow*). *D*, lateral angiogram demonstrating contrast extravasation (*arrow*) from the vertebrobasilar junction after stent deployment and vessel rupture.

hyperplasia, and another patient exhibited 40% narrowing of the vessel lumen, compared with the lumen diameter immediately after stenting. One patient with good patency of the stented lesion exhibited luminal narrowing proximal to the stent, with a pseudoaneurysm at the stent (Fig. 3).

DISCUSSION

Historical perspective

Symptomatic vertebrobasilar artery stenosis portends a poor prognosis. The Warfarin-Aspirin Symptomatic Intracranial Disease Study Group observed that patients with 50 to 90% stenosis of the basilar artery who have experienced previous transient ischemic attacks or strokes have a 10.7% risk of recurrent strokes (10.7/100 patient-yr) in the territory of the stenotic vessel, despite medical therapy (31). The 11 patients

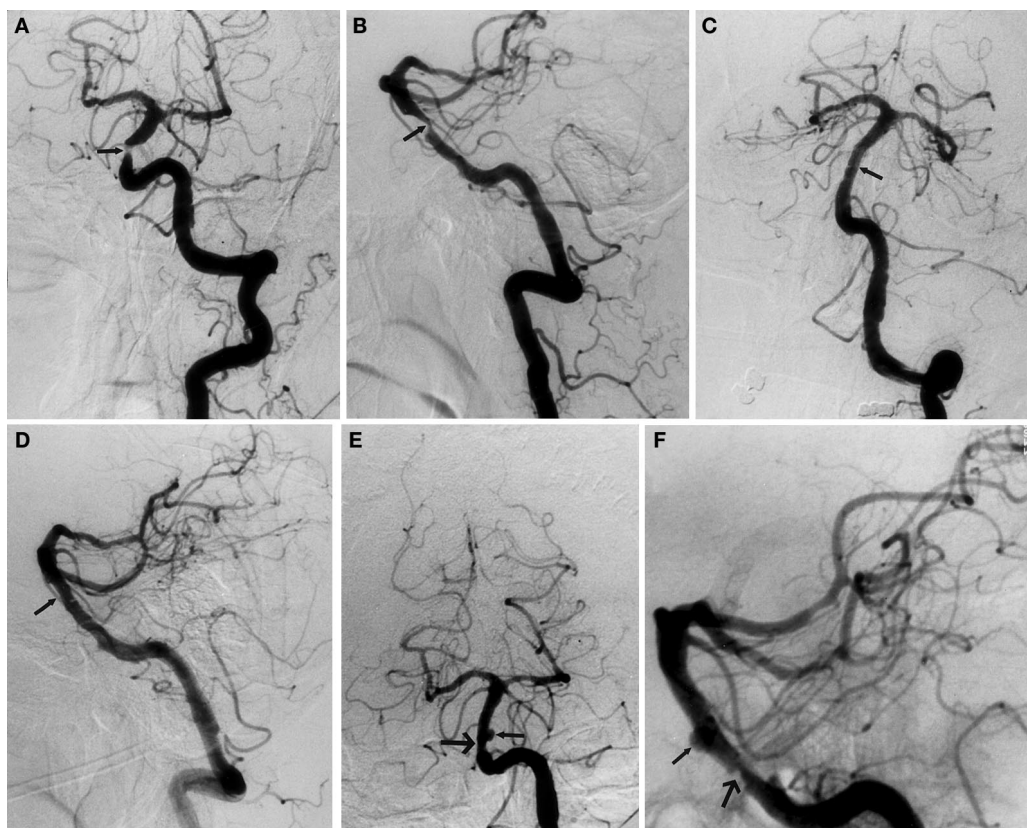

FIGURE 3. Patient 5. *A*, anteroposterior angiogram, showing basilar artery stenosis (arrow). *B*, lateral angiogram, showing basilar artery stenosis (arrow). *C*, anteroposterior angiogram obtained after angioplasty and stenting (arrow). *D*, lateral angiogram obtained after angioplasty and stenting (arrow). *E*, anteroposterior, 6-month follow-up angiogram, demonstrating an intrastent aneurysm (small arrow) and new basilar artery stenosis proximal to the stent (large arrow). *F*, lateral, 6-month follow-up angiogram, demonstrating the intrastent aneurysm (small arrow) and new basilar artery stenosis proximal to the stent (large arrow).

treated in our study experienced either recurrent transient ischemic attacks or strokes while receiving standard antiplatelet/anticoagulation therapy and thus likely warranted further therapeutic intervention after demonstration of the failure of best medical management.

Before the development of stent-assisted angioplasty, patients with significant vertebral or basilar artery stenosis were treated with technically demanding surgical bypass procedures or PTA. These surgical procedures are associated with significant complication rates, i.e., combined morbidity and mortality rates as high as 34% (2, 9, 27), which likely reflect the comorbidities exhibited by these patients in combination with their intracranial disease processes. Additionally, some patients with long basilar artery stenosis and significant comorbidities may not have surgical options.

PTA without stenting of the intracranial vasculature has produced results that are less than satisfactory. An early report by Ahuja et al. (1) described PTA for symptomatic basilar artery stenosis that resulted in complete occlusion, as observed on a 6-month follow-up angiogram. Another report of two cases of basilar artery stenosis treated with PTA alone demonstrated 50 to 60% restenosis on follow-up angiograms (24). A series reported by McKenzie et al. (17) revealed an incidence of moderate-to-severe restenosis of 35%, as well as an incidence of complications involving dissection of nearly 20%. Takis et al. (28) described a periprocedural stroke rate of 40% after PTA, which was attributable to vasospasm or perforator occlusion. Clark and Barnwell (5) reported a 30-day

morbidity rate of 11.7%, and Terada et al. (29) reported a 30% procedural complication rate. In a review by Jimenez et al. (11), only 33% of patients who underwent angioplasty alone exhibited sufficient improvement in lumen diameter.

Perhaps the best report on intracranial stenoses and angioplasty is that by Mori et al. (19). Those authors observed that restenosis and stroke risks after PTA were dependent on lesion morphological features. Lesions were divided into three groups on the basis of their morphological features. Type A lesions were less than 5 mm in length and concentric or moderately eccentric, without complete occlusion; Type B lesions were 5 to 10 mm, eccentric or occlusive, and less than 3 months old; and Type C lesions were greater than 10 mm, tortuous, occlusive, and more than 3 months old. According to that study, Type A lesions were most suitable for angioplasty. Stroke risks were 8, 26, and 87% for Groups A, B, and C, respectively. One-year restenosis rates were 0, 33, and 100% for treated lesions in Groups A, B, and C, respectively. As in the report on PTA alone by Mori et al. (19), Type B and C lesions exhibited poor outcomes with stent-assisted angioplasty in our series. In a later report by Mori et al. (20), those authors described stent-assisted angioplasty for 12 lesions in 10 patients, 6 of whom exhibited vertebrobasilar stenoses. Although the procedure was aborted for two of the six patients with vertebrobasilar artery stenoses, clinical success was achieved for 80% of the patients without morbidity or death.

Stent-assisted angioplasty

The concept of using intracranial stent-assisted angioplasty to treat medically refractory, symptomatic, intracranial, vascular stenosis was based on experience with cardiac intervention. Coronary vessel angioplasty is associated with a 5% rate of abrupt luminal narrowing and closure attributable to elastic vascular recoil and/or vessel dissection. These risks increase to 28% in the presence of thrombus (3). Recent advances in coronary stent technology have made it possible for clinicians to navigate stents through the often-tortuous proximal posterior circulation vasculature. Such stents have provided clinicians with novel therapeutic options for diseases with high morbidity rates and poor prognoses (30). The utility of cerebrovascular stents was first described for stent-assisted coil treatment of aneurysms. Several reports demonstrated the efficacy of stent-assisted coil treatment of difficult-to-treat, wide-necked aneurysms in both the anterior and posterior circulation (7, 26). In 1997, Higashida et al. (6) described one of the first cases of stent-assisted coil treatment of a fusiform basilar artery aneurysm. Sekhon et al. (26) described the successful treatment of a wide-necked vertebral artery aneurysm with a similar technique. The use of intracranial subarachnoid arterial stenting to treat vertebrobasilar artery stenosis was initially described by both Phatouros et al. (25) and Mori et al. (22). Although the patient died as a result of cardiogenic shock, a good angiographic outcome was achieved. In 1999, Horowitz et al. described the successful use of stent-assisted angioplasty to treat mid-basilar artery stenoses in three patients (10). As previously mentioned, in 2000 Mori et al. (20) reported vertebrobasilar artery stenosis of six patients (eight lesions) that was treated with stent-assisted angioplasty. Although the procedure was aborted for two patients because of tortuous vascular anatomic features, no morbidity or death was reported.

Complications and lessons learned

We learned several valuable lessons from the complications we observed, and we consequently changed the indications we consider for this procedure. It seems that the length of the stenosis affects the safety of the procedure, because three of four complications occurred with Mori Type B or C lesions. The vertebral artery rupture presented in *Figure 2* might have been caused by angioplasty being performed on a congenitally hypoplastic vessel, although the length of the stenotic segment was probably an additional contributing factor. We do not think that the two arterial ruptures occurred as a result of balloon overinflation. The pontine infarction we observed occurred in a patient with a long stenotic lesion (Mori Class C) and was likely attributable to occlusion of a perforator by the struts of the stent, although we cannot eliminate the possibility of an embolus or small dissection after angioplasty as the cause. Although the aneurysm in the case illustrated in *Figure 3* did not cause clinical compromise, it represents another serious complication associated with angioplasty-induced dissection.

As demonstrated by our report, stent-assisted angioplasty of the basilar and vertebral arteries is not free from procedure-related death and morbidity. It is clear that the natural history of

symptomatic vertebrobasilar stenosis often involves devastating or lethal infarctions, with a 7% annual risk of stroke (4). A stroke rate of nearly 11% with severe stenosis of the vertebrobasilar system, despite medical therapy (31), is unacceptable for most patients, and alternative therapies must be offered. Before the introduction of endovascular techniques, surgery to treat vertebrobasilar insufficiency effectively eliminated symptoms, with a patency rate of 95% (8). However, significant postoperative morbidity occurred in nearly one-third of cases, with a higher rate of complications in cases involving distal vertebral and low/mid-basilar artery stenoses. Although our results demonstrate that endovascular stent-assisted angioplasty has morbidity and mortality rates similar to those of surgical management, this treatment modality offers therapy to patients with unacceptable surgical risks. The technique of stent-assisted angioplasty to treat vertebrobasilar stenosis is still in its infancy, and the benefit/risk ratio of this procedure will improve as more laboratory and clinical data are reported. Given our sample size, it is difficult to accurately associate lesion morphological features, lesion location, or stent type with the likelihood of an adverse outcome. However, we do know, from the experience of Mori et al. (19, 20) with angioplasty alone, that Type B and C lesions fare poorly. It is our hope that, with improvements in stent technology, such as more compliant balloon catheters, fewer complications will occur.

CONCLUSION

Recent advances in coronary stent technology have allowed the development of a new generation of stents with the ability to negotiate tortuous vessels in the proximal portions of the posterior cerebrovascular circulation. The use of stent-assisted angioplasty to treat symptomatic, medically refractory, intracranial, vertebrobasilar artery stenosis may alleviate symptoms and alter the typically poor prognosis of this disease process. Although this series demonstrates the potential efficacy of stent-assisted angioplasty in the posterior circulation, it also demonstrates the morbidity and mortality risks associated with dilation of stenotic, often-fragile, diseased vessels. Longer-term clinical and angiographic follow-up monitoring will be required to determine whether the treatment of symptomatic, critical, medically recalcitrant, intracranial, vertebrobasilar artery stenoses using stent-assisted angioplasty will improve on the natural history of the disease with medical management alone.

Received, May 26, 2000.

Accepted, January 22, 2001.

Reprint requests: Michael Horowitz, M.D., Department of Neurological Surgery, University of Pittsburgh Medical Center, Suite B-400, 200 Lothrop Street, Pittsburgh, PA 15213-2582. Email: horowitz@neuronet.pitt.edu

REFERENCES

1. Ahuja A, Guterma LR, Hopkins LN: Angioplasty for basilar artery atherosclerosis: Case report. *J Neurosurg* 77:941-944, 1992.
2. Ausman JI, Shrontz CE, Pearce JE, Diaz FG, Crecelius JL: Vertebrobasilar insufficiency: A review. *Arch Neurol* 42:803-808, 1985.

3. Baim DS: Coronary angioplasty, in Baim DS, Grossman W (eds): *Cardiac Catheterization, Angiography, and Intervention*. Baltimore, Williams & Wilkins, 1995, pp 537-579.
4. Cartledge N, Whisnant J, Elveback LR: Carotid and vertebral-basilar transient cerebral ischemic attacks: A community study. *Mayo Clin Proc* 52:117-120, 1977.
5. Clark WM, Barnwell SL: Endovascular treatment for acute and chronic brain ischemia. *Curr Opin Neurol* 9:62-67, 1996.
6. Higashida RT, Smith W, Gress D, Urwin R, Dowd RF, Balousek PA, Halbach VV: Intravascular stent and endovascular coil placement for a ruptured fusiform aneurysm of the basilar artery: Case report and review of the literature. *J Neurosurg* 87:944-949, 1997.
7. Higashida RT, Tsai FY, Halbach VV, Dowd CF, Hieshima GB: Cerebral percutaneous transluminal angioplasty. *Heart Dis Stroke* 2:497-502, 1993.
8. Higashida RT, Tsai FY, Halbach VV, Dowd CF, Smith T, Fraser K, Hieshima GB: Transluminal angioplasty for atherosclerotic disease of the vertebral and basilar arteries. *J Neurosurg* 78:192-198, 1993.
9. Hopkins LN, Martin NA, Hadley MN, Spetzler RF, Budny J, Carter LP: Vertebrobasilar insufficiency: Part 2—Microsurgical treatment of intracranial vertebrobasilar disease. *J Neurosurg* 66:662-674, 1987.
10. Horowitz MB, Pride GL, Graybeal DF, Purdy PD: Percutaneous transluminal angioplasty and stenting of midbasilar stenoses: Three technical case reports and literature review. *Neurosurgery* 45:925-930, 1999.
11. Jimenez C, Duong H, Olarte M, Pile-Spellman J: Recurrent abrupt occlusion after transluminal angioplasty for basilar artery stenosis: Case report. *Neurosurgery* 44:210-215, 1999.
12. Kellog JX, Nesbit GM, Clark JM, Barnwell SL: The role of angioplasty in the treatment of cerebrovascular disease. *Neurosurgery* 43:549-556, 2000.
13. Kimura T, Yokoi H, Nakagawa Y, Tamura T, Kaburagi S, Sawada Y, Soto Y, Pokoi H, Hamasaki N, Nosaka H: Three-year follow-up after implantation of metallic coronary-artery stents. *N Engl J Med* 334:561-566, 1996.
14. Lanzino G, Fessler RD, Miletich RS, Guterman LR, Hopkins LN: Angioplasty and stenting of basilar artery stenosis: Technical case report. *Neurosurgery* 45:404-407, 1999.
15. Levy EI, Firlik AD, Wisniewski S, Rubin G, Jungeis C, Wechsler LR, Yonas H: Factors affecting survival rates for acute vertebrobasilar artery occlusions treated with intra-arterial thrombolytic therapy: A meta-analytical approach. *Neurosurgery* 45:539-545, 1999.
16. Malek AM, Higashida RT, Halbach VV, Phatouros CC, Meyers PM, Dowd CF: Tandem intracranial stent deployment for treatment of an iatrogenic, flow-limiting, basilar artery dissection: Technical case report. *Neurosurgery* 45:919-924, 1999.
17. McKenzie JD, Wallace RC, Dean BL, Flom RA, Khayata MH: Preliminary results of intracranial angioplasty for vascular stenosis caused by atherosclerosis and vasculitis. *AJNR Am J Neuroradiol* 17:263-268, 1996.
18. Mericle RA, Lanzino G, Wakhloo AK, Guterman LR, Hopkins LN: Stenting and secondary coiling of intracranial internal carotid artery aneurysm: Technical case report. *Neurosurgery* 43:1229-1234, 1998.
19. Mori T, Fukuoka M, Kazita K, Mori K: Follow-up study after intracranial percutaneous transluminal cerebral balloon angioplasty. *AJNR Am J Neuroradiol* 19:1525-1533, 1998.
20. Mori T, Kazita K, Chokyu K, Mima T, Mori K: Short-term arteriographic and clinical outcome after cerebral angioplasty and stenting of carotid and atherosclerotic occlusive disease. *AJNR Am J Neuroradiol* 21:249-254, 2000.
21. Mori T, Kazita K, Kimihiko C, Tatsuo M, Mori K: Short-term arteriographic and clinical outcome after cerebral angioplasty and stenting for intracranial vertebrobasilar and carotid atherosclerotic occlusive disease. *AJNR Am J Neuroradiol* 21:249-254, 2000.
22. Mori T, Kazita K, Mori K: Cerebral angioplasty and stenting for intracranial vertebral atherosclerotic stenosis. *AJNR Am J Neuroradiol* 20:787-789, 1999.
23. Morris PP, Martin EM, Regan J, Braden G: Intracranial deployment of coronary stents for symptomatic atherosclerotic disease. *AJNR Am J Neuroradiol* 20:1688-1694, 1999.
24. Nakatsuka H, Ueda T, Ohta S, Sakaki S: Successful percutaneous transluminal angioplasty for basilar artery stenosis: Technical case report. *Neurosurgery* 39:161-164, 1996.
25. Phatouros CC, Higashida RT, Malek AM, Smith WS, Mully TW, DeArmond SJ, Dowd CF, Halbach VV: Endovascular stenting of an acutely thrombosed basilar artery: Technical case report and review of the literature. *Neurosurgery* 44:667-673, 1999.
26. Sekhon LH, Morgan MK, Sorby W, Grinnell V: Combined endovascular stent implantation and endosaccular coil placement for the treatment of a wide-necked vertebral artery aneurysm: Technical case report. *Neurosurgery* 43:380-383, 1998.
27. Spetzler RF, Hadley MN, Martin NA, Hopkins LN, Carter LP, Budny J: Vertebrobasilar insufficiency: Part 1—Microsurgical treatment of extracranial vertebrobasilar disease. *J Neurosurg* 66:648-661, 1987.
28. Takis C, Kwan ES, Pessin MS, Jacobs DH, Caplan LR: Intracranial angioplasty: Experience and complications. *AJNR Am J Neuroradiol* 18:1661-1668, 1997.
29. Terada T, Higashida RT, Halbach VV, Dowd CF, Nakai E, Yokote H, Itakura T, Hieshima GB: Transluminal angioplasty for arteriosclerotic disease of the distal vertebral and basilar arteries. *J Neurol Neurosurg Psychiatry* 60:377-381, 1996.
30. Wakhloo AK, Lanzino G, Lieber BB, Hopkins LN: Stents for intracranial aneurysms: The beginning of a new endovascular era? *Neurosurgery* 43:377-379, 1998.
31. Warfarin-Aspirin Symptomatic Intracranial Disease (WASID) Study Group: Prognosis of patients with symptomatic vertebral or basilar artery stenosis: The Warfarin-Aspirin Symptomatic Intracranial Disease (WASID) Study Group. *Stroke* 29:1389-1392, 1998.

COMMENTS

Levy et al. review 11 cases of intracranial vertebrobasilar stenosis treated with angioplasty and stenting. As the authors state, the natural history of untreated posterior circulation stenosis is dismal and new therapeutic methods must evolve to address the treatment of patients with this disease entity. Although endovascular therapy offers the allure of noninvasiveness, its efficacy has yet to be determined in this patient population. In fact, as the results of this study confirm, the use of intracranial stents is fraught with potential hazards. Arterial rupture, malposition of the stent, and the inability to pass the stent to the appropriate location are all factors complicating the use of this technology. This work adds to our understanding of the endovascular management of this disease and elucidates pitfalls that future research will undoubtedly address, specifically, how endovascular methods and equipment need to be

modified to treat this pathological entity more safely and effectively.

Felipe C. Albuquerque
Cameron G. McDougall
Phoenix, Arizona

Levy et al. report their experience with 11 cases of stent-assisted revascularization of the posterior circulation. They review the rapidly expanding literature concerning this difficult therapeutic dilemma in which significant advances are being made.

It is important to keep in mind the experience of Mori et al. (1). In their series of stent-assisted angioplasties of 12 lesions in 10 patients, 6 of which were due to vertebrobasilar stenosis, the patients were managed on a case selection basis. In this small group, the procedure was aborted twice, because of either the inability to reach the lesion or the assessed high risk of treatment. Long segments, obviously, are more difficult to treat.

The two cases shown in this article (*Figs. 2 and 3*) demonstrate that knowledge of the anatomic variants in the vertebrobasilar circulation is imperative to avoid the type of complications depicted in these two cases. In the case illustrated in *Figure 2*, the rupture occurs just distal to the posteroinferior cerebellar artery (PICA). The sizes of the PICA and the proximal and distal vertebral arteries, although narrow, are symmetrical. Therefore, dilation of this area predictably carries a higher risk of vessel rupture. It may be impossible to dilate a vessel that is embryonically of appropriate caliber, and balloon-assisted stent dilation is probably contraindicated. In this particular case, it would be interesting to see the opposite vertebral artery and the carotid system.

In the case illustrated in *Figure 3*, it is interesting to note the area of stenosis in the basilar artery segment, where there is a prominent right anteroinferior cerebellar artery vessel. The distal position of the stent is at the level of the PICA on the left. Although it is not well seen, I believe that there is a prominent PICA trunk on the right. It would therefore not be unexpected to find a small vessel at the area of stenosis—and, in fact, this may be the etiology of the symptoms. In any event, this is the region in which the aneurysm developed. The question is: if the authors had crossed the anteroinferior cerebellar arteries and had not left the edge of the stent at that level, would this type of finding have been avoided? In addition, what is the natural history of this small aneurysm? In the future, revascularization in the craniocerebral area will take a more anatomophysiological approach, and functional revascularization will be the primary method for improving global cerebrovascular perfusion.

Alex Berenstein
Interventional Neuroradiologist
New York, New York

-
1. Mori T, Kazita K, Chokyu K, Mima T, Mori K: Short-term arteriographic and clinical outcome after cerebral angioplasty and stenting of carotid and atherosclerotic occlusive disease. *AJNR Am J Neuroradiol* 21:249–254, 2000.

In their article, Levy et al. offer a frank look at the dangers of treating vertebrobasilar ischemia. In the future, their series will serve as a benchmark from which to measure our progress in treating unstable posterior circulation occlusive vascular disease. It strikes the reader that the mortality in this series is no better than the natural history or the results of the surgical bypass procedures that are “fraught with complications.” The authors report a mortality rate of 36% (4 of 11 patients), which is strikingly similar to the quoted surgical complication rate of 34%. The potential severity of these complications cannot be overstated. As reported in *Table 3*, two patients with fatal outcomes presented with minor symptoms (Modified Rankin Scale score, 1). Clearly, intervention must be considered only with the greatest of caution. The sole advantage of stent-assisted angioplasty over surgical procedures is the ability to access more distal lesions without a significant change in procedural risk.

The authors' Discussion section is particularly enlightening with regard to procedural risks. Their experience would indicate that lesion morphology plays a significant role in determining procedural outcome. Mori Type B and C lesions fared worse in this series, although no statistical comparison can be made, owing to the small sample size. With respect to the pontine infarction reported, we would comment that stent strut occlusion of a perforating artery is not the only explanation; it is more likely that the atherosclerotic plaque was fractured and compressed across the perforator, resulting in occlusion. We have not seen ischemic symptoms related to intracranial stenting for nonatherosclerotic lesions, including aneurysms of the basilar artery, despite crossing significant lengths of normal artery and, presumably, sites of origin of perforating branches.

Andrew J. Ringer
L. Nelson Hopkins
Buffalo, New York

Levy et al. describe their experience in treating 11 patients with stent-assisted angioplasty of the basilar or vertebral arteries. I think one should keep in mind that these patients have an extremely poor prognosis when they are medically intractable. In very experienced hands, there were nevertheless three periprocedural deaths and one delayed death resulting from a pontine infarction. Other complications that the authors describe include a second pontine infarction with subsequent diplopia. One patient also developed a delayed pseudoaneurysm at the site of the angioplasty. When these types of problems are associated with a technique or procedure, many eyebrows are elevated; however, one must consider that there is a 10.7% risk of recurrent stroke in patients who are medically refractory. The only other alternative is extracranial-intracranial bypass and, as the authors report, this procedure carries a significant risk in and of itself.

Many of the anecdotal reports in the literature on stent-assisted angioplasty in the posterior circulation refer to the Mori classification as it relates to complications. Certainly, there is a recurring theme that Mori Type B and C lesions tend to do poorly for the reasons the authors allude to. The advent

of abciximab (ReoPro; Eli Lilly and Co., Indianapolis, IN) and other IIb/IIIa platelet inhibitors may ultimately result in a decreased incidence of delayed myointimal fibrosis and some of the other associated periprocedural embolic events.

The authors have achieved technical success in dealing with a very difficult patient population. As technology improves and the learning curve is elevated, morbidity and mortality will certainly decline, as we have seen with other new procedures.

Robert H. Rosenwasser
Philadelphia, Pennsylvania

Levy et al. present their experience with the use of percutaneous angioplasty and stenting of the vertebral and/or basilar artery in patients who presented with posterior fossa ischemia/infarction after the failure of intense medical therapy. The present generation of balloon-stent systems (most of them inherited from the cardiologist's armamentarium) allowed the authors successfully to deploy these systems at the cranial base in areas of symptomatic stenosis involving distal vertebral and proximal basilar arteries.

The article emphasizes procedural morbidity and midterm anatomic and clinical outcomes in patients harboring a disease with a very poor natural history. Their results are similar to those reported in the literature, and the authors emphasize that this technology needs to be used in very selective cases of patients with posterior fossa circulation ischemia and poor collateral circulation after the failure of intense medical therapy. This statement is particularly true with regard to patients harboring symptomatic stenosis of the basilar artery.

The present generation of small angioplasty balloons and stents have enough "trackability" to be able to negotiate the challenging curves of the vertebral artery around the lateral mass of the C1 vertebra and then be deposited along the direct course of the vertebral or basilar arteries. In a limited number of cases, this intracranial navigation may be hampered by the

tortuosity of the vertebrobasilar system and the presence of proximal stenosis. We agree with the authors that the length and symmetry of the stenosis play an important role in the final anatomic outcome. The shorter and more midline situation of the stenosis, the higher the possibility of achieving a successful arterial angioplasty and stenting.

In *Figure 2*, the authors show a procedural complication (arterial rupture) in a vertebral stenosis that they classify as Mori Type B. I take the liberty of disagreeing with the authors' anatomic evaluation of this lesion. The right vertebral artery "stenosis" was the angiographic appearance of a congenital hypoplasia and not of an atherosclerotic long stenosis. This same pitfall may be encountered in cases of symptomatic vasospasm after subarachnoid hemorrhage when the interventional neuroradiologist performs a balloon angioplasty of a hypoplastic M1 portion of the posterior cerebral artery, believing that the angiographic narrowing is related to a spastic normal artery.

This article also emphasizes the limited predictability relating to the procedural morbidity of angioplasty and stenting of the basilar artery trunk. We may have an appropriate technical control of balloon-stent navigation and deployment, but we are blind as to the location of brainstem perforators. This anatomic challenge will be very difficult to overcome, even if we develop an appropriate imaging modality that will show the relationship of these vessels to the lesion being treated.

The anatomic results and procedural and clinical outcomes presented in this article are true representations of the present state of this technology when applied in the posterior circulation. Future technical improvements in balloon-stent combinations will make this technique easier to use but will not erase the challenge raised by the unpredictable location of brainstem perforators.

Fernando Viñuela
Interventional Neuroradiologist
Los Angeles, California

Congress of Neurological Surgeons/American Association of Neurological Surgeons Joint Section Chairmen

Cerebrovascular Surgery: Issam A. Awad, Denver, Colorado

Disorders of the Spine and Peripheral Nerves: Curtis A. Dickman, Phoenix, Arizona

History of Neurological Surgery: T. Forcht Dagi, Atlanta, Georgia

Neurotrauma and Critical Care: M. Ross Bullock, Richmond, Virginia

Pain: Kenneth A. Follett, Iowa City, Iowa

Pediatric Neurological Surgery: John P. Laurent, Houston, Texas

Stereotactic and Functional Neurosurgery: Philip L. Gildenberg, Houston, Texas

Tumors: Joseph M. Piepmeier, New Haven, Connecticut