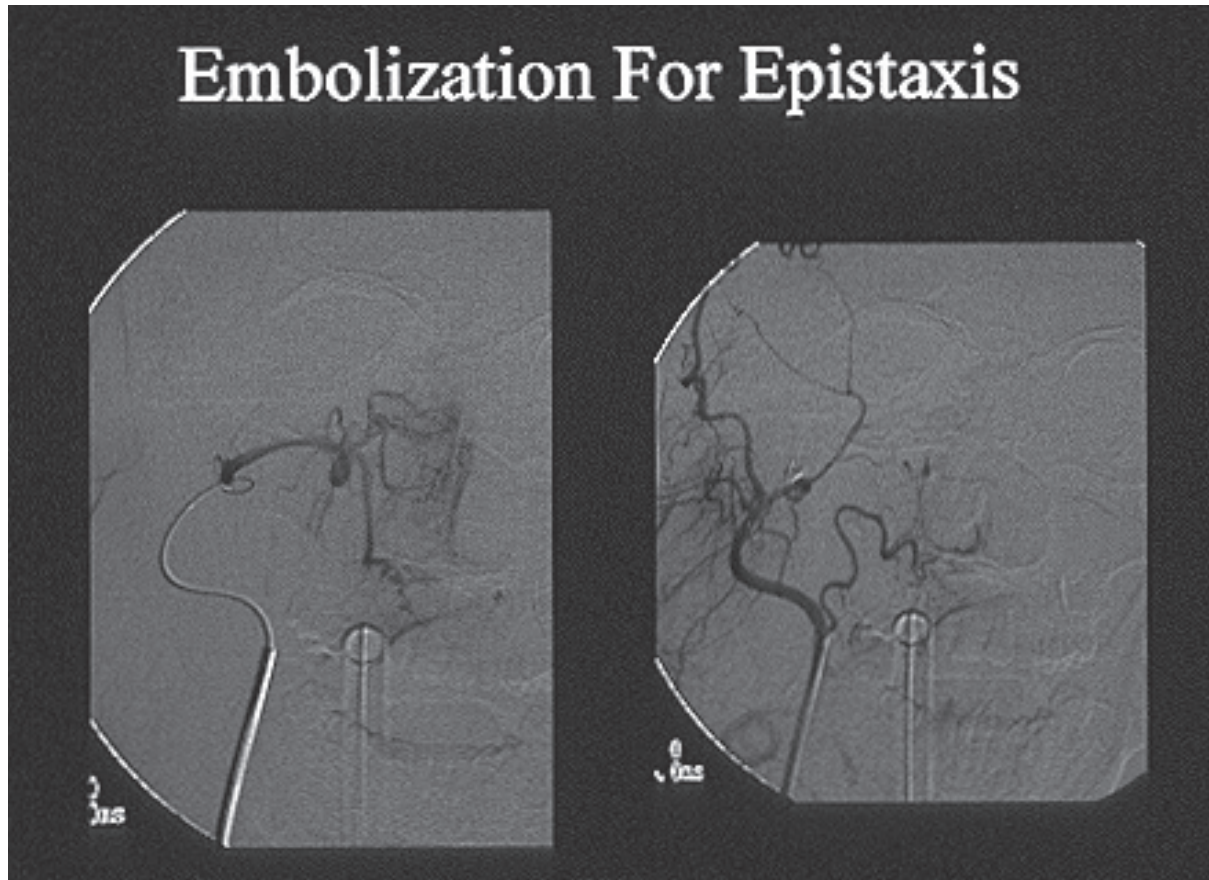


TREATMENT OF UNCONTROLLABLE OR RECURRENT NOSE BLEEDS (EPISTAXIS)

Case Report

A 70 year old man presents to the ER at 10 PM for the fourth time over a six month period with recurrent nosebleeds that have required packing on three occasions and transfusion of 4 units of packed red blood cells. The patient was taken directly to the angiography suite where he underwent transfemoral catheterization of the internal maxillary arteries and facial arteries under IV sedation. Each vessel was superselectively catheterized using a 0.021 inch microcatheter. Angiographic imaging showed hypervascular nasal mucosa, but no evidence for an actively bleeding site. Prior to embolization, 3 cc of preservative free Lidocaine were injected into each vessel. Vision was tested and there was no change in the patient's acuity thus indicating that no dangerous connections between the ethmoidal arteries and ophthalmic arteries were present. The right and left internal maxillary arteries and right and left facial arteries were then embolized using 250 micron polyvinyl spheres (Embospheres, Merit Medical, Jordan, UT). Procedure time was 37 minutes. The patient was discharged 6 hours following his procedure with no active bleeding and no packing. No recurrence was reported.

The left sided figure below shows a microcatheter positioned in the right internal maxillary artery. The AP angiographic image demonstrates hypervascular right nasal mucosa. The right sided figure shows an angiographic image after embolization. Note the lack of contrast filling the midline nasal region that was seen on the right sided image prior to embolization.



Definition

Epistaxis is the medical term for acute hemorrhage from the nostril, nasal cavity, or oropharynx (aka: nosebleed). While most cases of epistaxis are self-limiting and simple to address, there are some instances in which nasal bleeding can be annoyingly recurrent and resistant to therapy.

Clinical Importance

Ten percent of nosebleeds are considered serious. These events can lead to airway compromise and/or significant blood loss.

Classifications

Two types of epistaxis exist.

Anterior nosebleeds tend to arise from the septum where Kiesselbach's plexus, a prominent vascular territory, can be found. These bleeds are most common and generally respond to simple therapies such as compression or local packing.

Posterior nosebleeds generally arise from Woodruff's plexus which is a venous plexus located in the posterior inferior meatus. These bleeds are less common, prolonged, difficult to control, and can present with bilateral nostril bleeding and bleeding into the oropharynx. Posterior nosebleeds are responsible for the majority of cases that require medical attention.

Etiologies

Recurrent epistaxis may be secondary to local trauma (nose picking), low relative humidity leading to dry and friable mucous membranes, respiratory infections, chronic sinusitis, rhinitis and environmental irritants that cause mucosal inflammation.

While most instances of serious or recurrent epistaxis are due to relatively benign insults, some cases can result from some more significant underlying etiologies. These causes include:

Coagulopathy

- Liver disease with factor deficiency
- Hemophilia
- Leukemia
- Drug interactions (anticoagulants, antiplatelet agents, nasal steroids, cocaine)
- Von Willibrand's Disease
- HIV
- Leukemia

Inflammation

- Lupus erythematosus
- Granulomatosis with polyangiitis

Neoplasms

- Squamous cell carcinoma
- Adenoid cystic carcinoma
- Melanoma
- Carcinoma
- Juvenile Nasopharyngeal Angiofibroma

Trauma

- Septal spurs
- Blunt injury with associated fractures
- Surgical trauma

Post-Radiation mucosal vascular abnormalities

Vascular malformations

Hereditary hemorrhagic telangiectasia (Osler-Weber-Rendu disease)
Septal arteriovenous malformations
Aneurysm

Hypertension

Treatments

Anterior nosebleeds are generally treated with manual compression over Kiesselbach's plexus, local packing, and at times application of vasoconstrictive agents such as oxymetazoline or phenylephrine.

Posterior nosebleeds generally require medical attention and more advanced approaches. These treatments can include the following:

Nasal Packing

Nasal packing can be achieved using cotton gauze, collagen materials, nasal tampons, and inflatable balloon catheters (Rapid Rhino, Smith and Nephew, Austin, TX; Foley Catheter). These materials/devices are often left in place for 24-48 hours. As with placement, removal is generally performed by an otolaryngologist. If recurrent bleeding occurs following removal, other more invasive treatments can be considered.

Nasal packing is uncomfortable and at times painful and poorly tolerated. Complications can include septal and mucosal necrosis, infection, septal hematomas, sinusitis and toxic shock syndrome.

Cauterization

Silver nitrate can be used to control posterior epistaxis by applying the chemical to the actively bleeding site to affect burning and resultant vessel occlusion. The use of a topical anesthetic is advised prior to agent application.

Open Surgery

When epistaxis that does not respond to the above therapies or such therapies cannot be tolerated (packing), open surgical ligation of the sphenopalatine, anterior/posterior ethmoidal arteries, and potentially the internal maxillary artery must be considered.

Endovascular Surgery

Endovascular surgery is a potent tool for the management of posterior epistaxis. During this procedure a small catheter is advanced from the femoral artery, through the aorta and into the external carotid artery. The catheter is then sequentially

advanced into the internal maxillary artery and facial artery. These vessels are then occluded distally using injected embolic particles or liquid adhesives. In general both the right and left internal maxillary arteries and facial arteries are embolized during a single procedure to reduce the risk of residual or recurrent bleeding.

We have found the advantages of an endovascular approach to recurrent posterior epistaxis are the following:

1. Control of bleeding can be achieved quickly and effectively (procedure time is generally less than 30 minutes)
2. Vascular anatomy can be radiographically accurately identified
3. Vascular occlusion and devascularization of the nasal mucosa can be confirmed radiographically
4. Packing can be removed immediately after the procedure thus reducing the risks and discomfort associated with prolonged packing
5. Embolization does not require general anesthesia unless the airway is compromised in a supine position by blood running posteriorly into the oropharynx
6. Embolization is painless
7. Complication rate is low (less than 1%).
8. Endovascular therapy does not require use of the operating room that can often expedite care and reduce costs.

Conclusion

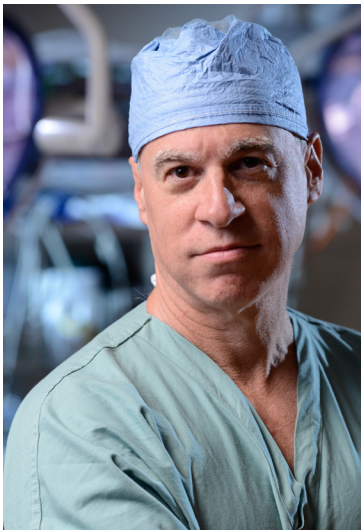Epistaxis (nose bleed) is generally a benign event that can be managed with simple compression. However, when such events are generated from the posterior nasal cavity they can be recurrent and dangerous. Such bleeds often require more sophisticated treatments as outlined above. We have found that early application of endovascular techniques can rapidly address bleeding in a painless and low risk manner while effectively reducing the incidence of recurrence.



Dr. Michael Horowitz

Dr. Michael Horowitz provides comprehensive medical and neurosurgical care for patients in Orange Park and the surrounding communities. He treats a wide range of conditions including spine and cranial/brain surgery and has specialized interests in vascular neurology, stroke, cranial nerve disorders, brain tumors and hydrocephalus. Offering compassionate, experienced, and a detail-oriented approach, Dr. Horowitz believes in a patient-centered delivery of care.

Dr. Horowitz is Board Certified in Neurological Surgery and Fellowship trained in Endovascular Neurosurgery. He received his medical degree from the University of Rochester School of Medicine and Dentistry. He then completed his residency from the University of Pittsburgh and fellowship from University of Texas. In addition to his clinical activities, Dr. Horowitz is heavily interested in academic pursuits. He has published over 150 peer reviewed journal articles, over 45 book chapters, and has edited a text on Endovascular Neurosurgery.



Conditions and Services

- Aneurysms
- Angioma
- Brain Tumor
- Brain Surgery
- Carotid Stenosis
- Cerebral Hemorrhage
- Epilepsy
- Embolization
- Glioma
- Microsurgery
- Scoliosis
- Stroke



1887 Kingsley Avenue, Suite 1900 | Orange Park, FL 32073
Phone: (904) 276-7336 | Fax: (904) 276-7337

OrangeParkPhysicians.com